CHAPTER 8

Skin Disorders and Diseases

Chapter Outline

Learning Objectives

After completing this chapter, you will be able to:

- ✓ **LO1** Recognize common skin lesions.
- ✓ **LO2** Describe the disorders of the sebaceous glands.
- ✓ **LO3** Name and describe changes in skin pigmentation.
- ✓ **LO4** Identify the forms of skin cancer.
- ✓ **LO5** Understand the two major causes of acne and how to treat them.
- ✓ **LO6** List the factors that contribute to the aging of the skin.
- ✓ **LO7** Explain the effects of overexposure to the sun on the skin.
- ✓ **LO8** Understand what contact dermatitis is and know how it can be prevented.

Key Terms

Page number indicates where in the chapter the term is used.

albinism
pg. 183

allergic contact dermatitis (ACD)
pg. 190

anaerobic
pg. 186

anhidrosis
pg. 181

basal cell carcinoma
pg. 184

bromhidrosis
pg. 181

bulla
pg. 178

chloasma (liver spots)
pg. 183

closed comedo (whitehead)
pg. 180

conjunctivitis (pinkeye)
pg. 182

contact dermatitis
pg. 190

crust
pg. 179

cyst
pg. 178

dermatitis
pg. 182

dyschromias
pg. 183

eczema
pg. 182

excoriation
pg. 180

extrinsic factors
pg. 187

fissure
pg. 180

free radicals
pg. 188

herpes simplex
pg. 182

hyperhidrosis
pg. 181

hyperpigmentation
pg. 183

hypertrophy
pg. 184

hypopigmentation
pg. 183

impetigo
pg. 182

intrinsic factors
pg. 187

irritant contact dermatitis (ICD)
pg. 191

keloid
pg. 180

keratoma
pg. 184

lentigines
pg. 183

Key Terms

Page number indicates where in the chapter the term is used.

lesion
pg. 178

leukoderma
pg. 183

macule
pg. 178

malignant melanoma
pg. 184

milia
pg. 180

miliaria rubra (prickly heat)
pg. 181

mole
pg. 184

nevus (birthmark)
pg. 183

nodule
pg. 178

noncomedogenic
pg. 187

primary lesions
pg. 178

psoriasis
pg. 182

retention hyperkeratosis
pg. 186

rosacea
pg. 181

scale
pg. 180

scar (cicatrix)
pg. 180

sebaceous cyst
pg. 181

seborrheic dermatitis
pg. 181

secondary skin lesions
pg. 179

sensitization
pg. 190

skin tag
pg. 184

squamous cell carcinoma
pg. 184

stain
pg. 183

tan
pg. 183

telangiectasis
pg. 181

tubercle
pg. 179

tumor
pg. 179

ulcer
pg. 180

verruca (wart)
pg. 184

vesicle
pg. 179

vitiligo
pg. 183

wheal
pg. 179

Are you interested in skin care? Have you always thought that it would be interesting to understand the way that the skin functions and how it can be improved and beautified? If so, then skin care is a possible area of specialty for you!

Skin care specialists are in high demand in many salons and spas and earn excellent salaries. Some stylists find caring for the skin less arduous and physically demanding than styling hair and choose to balance their day by scheduling services in both areas. Whatever your reason, skin care is an area of rapid change and growth and a topic on most clients' minds. Knowing the basics of skin care and how the skin functions will allow you to advise clients on their skin care regimens when they seek your professional opinion.

WHY STUDY SKIN DISORDERS AND DISEASES?

Cosmetologists should study and have a thorough understanding of skin disorders and diseases for the following reasons:

- In order to provide even the most basic of skin care services, you must understand the underlying structure of the skin and common skin problems.
- You must be able to recognize adverse conditions, including inflamed skin conditions, skin diseases, and infectious skin disorders, and you must know which of these conditions are treatable by the cosmetologist and which need to be referred to a medical doctor.
- Knowing about and being able to offer skin care treatments adds another dimension of service for your clients.

Disorders and Diseases of the Skin

Like any other organ of the body, the skin is susceptible to a variety of diseases, disorders, and ailments. In your work as a practitioner, you will often see skin and scalp disorders, so you must be prepared to recognize certain common skin conditions and know which you can help to treat and which must be referred to a physician. Occasionally, you may be asked to apply or use on a client a scalp treatment prescribed by a physician. These must be applied in accordance with a physician's directions.

A dermatologist is a physician who specializes in diseases and disorders of the skin, hair, and nails. Dermatologists attend four years of college, four years of medical school, and then about four

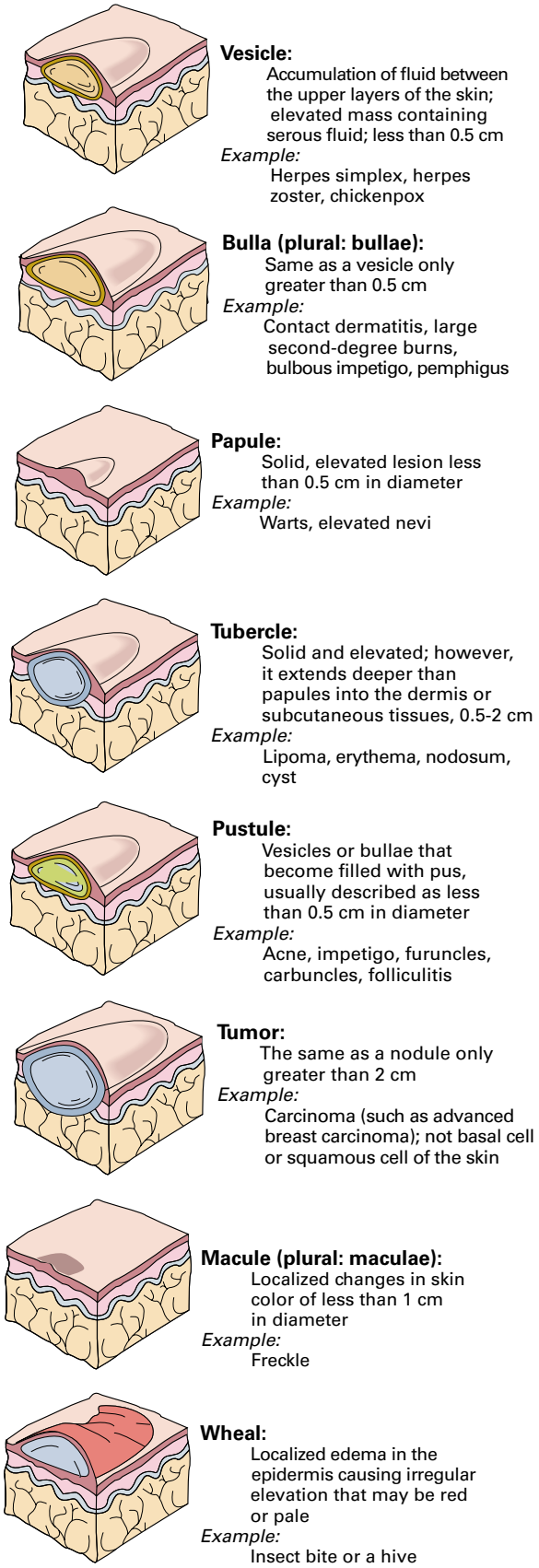

▲ **Figure 8–1**
Primary skin lesions. These illustrations show the size, elevation or depression, and layers of the skin that are affected in each type of lesion.

years of specialty training in dermatology. Many have additional training in internal medicine, because some skin symptoms may be reflective of internal disease. Cosmetologists refer clients with medical issues to dermatologists more than any other type of physician.

It is very important that a salon not serve a client who is suffering from an inflamed skin disorder, infectious or not, without a physician's note permitting the client to receive services. The cosmetologist should be able to recognize these conditions and sensitively suggest that proper measures be taken to prevent more serious consequences.

Numerous important terms relating to skin, scalp, and hair disorders that you should be familiar with are described in subsequent sections.

Lesions of the Skin

A **lesion** (LEE-zhun) is a mark on the skin that may indicate an injury or damage that changes the structure of tissues or organs. A lesion can be as simple as a freckle or as dangerous as a skin cancer. Lesions can indicate skin disorders or diseases and sometimes may indicate other internal diseases. Being familiar with the principal skin lesions will help you be able to distinguish between conditions that may and may not be treated in a salon or spa (**Figure 8–1**).

Primary Lesions of the Skin

The terms for different lesions listed below often indicate differences in the area of the skin layers affected and the size of the lesion.

Primary lesions are lesions that are a different color than the color of the skin and/or lesions that are raised above the surface of the skin. Requires medical referral.

Bulla (BULL-uh), (plural: bullae, BULL-ay), is a large blister containing a watery fluid; similar to a vesicle but larger (**Figure 8–2**). Requires medical referral.

Cyst (SIST) is a closed, abnormally developed sac that contains fluid, pus, semifluid, or morbid matter, above or below the skin. Cysts are frequently seen in severe acne cases. Requires medical referral.

Macule (MAK-yool), (plural: maculae, MAK-yuh-ly), is any flat spot or discoloration on the skin, such as a freckle or a red spot, left after a pimple has healed.

Nodule (NOD-yool) is a solid bump larger than .4 inches (1 centimeter) that can be easily felt. Requires medical referral.

Papule is a small elevation on the skin that contains no fluid but may develop pus. Papules are frequently seen in acne.

Pustule is a raised, inflamed, papule with a white or yellow center containing pus in the top of the lesion referred to as the head of the pimple (**Figure 8–3**).

▲ **Figure 8–2**
Bullae.

▲ **Figure 8–3**
Papules and pustules.

Tubercle (TOO-bur-kul) is an abnormal, rounded, solid lump above, within, or under the skin; larger than a papule. Requires medical referral.

Tumor (TOO-mur) is an abnormal mass varying in size, shape, and color. Tumors are sometimes associated with cancer, but the term *tumor* can mean any sort of abnormal mass. Requires medical referral.

Vesicle (VES-ih-kel) is a small blister or sac containing clear fluid, lying within or just beneath the epidermis. Poison ivy and poison oak, for example, produce vesicles (**Figure 8–4**). Requires medical referral.

Wheal (WHEEL) is an itchy, swollen lesion that lasts only a few hours; caused by a blow or scratch, the bite of an insect, urticaria (skin allergy), or the sting of a nettle. Examples include hives and mosquito bites.

▲ **Figure 8–4**
Poison oak vesicles.

Secondary Lesions

Secondary skin lesions are characterized by piles of material on the skin surface, such as a crust or scab, or by depressions in the skin surface, such as an ulcer (**Figure 8–5**).

Crust is dead cells that form over a wound or blemish while it is healing; an accumulation of sebum and pus, sometimes mixed with epidermal material. An example is the scab on a sore.

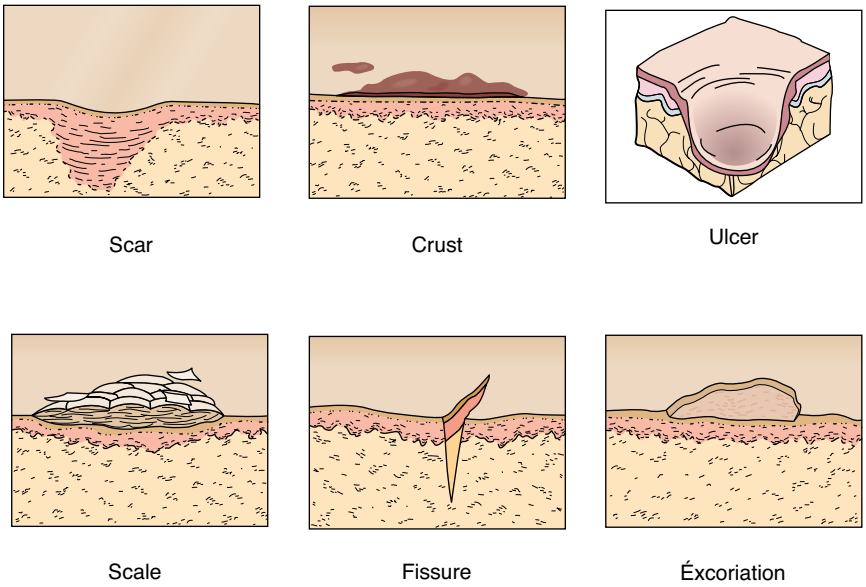

◀ **Figure 8–5**
Secondary skin lesions.

▲ Figure 8–6
Keloids.

Excoriation (ek-skor-ee-AY-shun) is a skin sore or abrasion produced by scratching or scraping.

Fissure (FISH-ur) is a crack in the skin that penetrates the dermis. Examples are severely cracked and/or chapped hands or lips.

Keloid (KEE-loyd) is a thick scar resulting from excessive growth of fibrous tissue (**Figure 8–6**).

Scale is any thin dry or oily plate of epidermal flakes. An example is abnormal or excessive dandruff.

Scar, also known as **cicatrix** (SIK-uh-triks), is a lightly raised mark on the skin formed after an injury or lesion of the skin has healed.

Ulcer (UL-sur) is an open lesion on the skin or mucous membrane of the body, accompanied by loss of skin depth and possibly weeping of fluids or pus. Requires medical referral. ☑ **LO1**

▲ Figure 8–7
Comedones.

Disorders of the Sebaceous (Oil) Glands

There are several common disorders of the sebaceous (oil) glands that the cosmetologist should be able to understand and identify.

An open comedo, also known as a blackhead, is a hair follicle filled with keratin and sebum. Comedones appear most frequently on the face, especially in the T-zone, the center of the face (**Figure 8–7**). When the sebum of the comedo is exposed to the environment, it oxidizes and turns black. When the follicle is closed and not exposed to the environment, the sebum remains a white or cream color and is a **closed comedo**, also known as **whitehead**, and appears as a small bump just under the skin surface.

Comedones can be removed by trained beauty professionals as long as proper procedures are employed and the procedure is performed in a sanitary environment using extraction implements that have been properly cleaned and disinfected.

▲ Figure 8–8
Milia.

Milia (MIL-ee-uh) are benign, keratin-filled cysts that appear just under the epidermis and have no visible opening. They resemble small sesame seeds and are almost always perfectly round. They are commonly associated with newborn babies but can appear on the skin of people of all ages. They are usually found around the eyes, cheeks, and forehead, and they appear as small, whitish masses (**Figure 8–8**). Depending on the state, milia can be treated in the salon or spa.

Acne, also known as acne vulgaris, is a skin disorder characterized by chronic inflammation of the sebaceous glands from retained secretions and bacteria known as propionibacterium acnes (P. acnes), the scientific term for acne bacteria. Acne will be discussed in further detail later in this chapter (**Figure 8–9**).

Sebaceous cyst is a large protruding pocket-like lesion filled with sebum. Sebaceous cysts are frequently seen on the scalp and the back. They should be removed surgically by a dermatologist.

Seborrheic dermatitis (seb-oh-REE-ick derm-ah-TIE-tus) is a skin condition caused by an inflammation of the sebaceous glands. It is often characterized by redness, dry or oily scaling, crusting, and/or itchiness (**Figure 8–10**). The red, flaky skin often appears in the eyebrows and beard, in the scalp and hairline, at the middle of the forehead, and along the sides of the nose. Mild flares of seborrheic dermatitis are sometimes treated with cortisone creams. Seborrheic dermatitis is a medical condition, but it can be helped in the salon with the application of non-fatty skin care products designed for sensitive skin. Severe cases should be referred to a dermatologist, who will often prescribe topical antifungal medications.

Rosacea (roh-ZAY-shuh), formerly called *acne rosacea*, is a chronic condition that appears primarily on the cheeks and nose. It is characterized by flushing (redness), **telangiectasis** (tee-lang-jek-tay-shuhz) (distended or dilated surface blood vessels), and, in some cases, the formation of papules and pustules. The cause of rosacea is unknown, but the condition is thought to be genetic. Certain factors are known to aggravate the condition in some individuals. These include exposure to heat, sun, and very cold weather; ingestion of spicy foods, caffeine, and alcohol; and stress. Rosacea can be treated and kept under control by using medication prescribed by a dermatologist, using proper skin care products designed for especially sensitive skin, and avoiding the aggravating flare factors listed above (**Figure 8–11**). ☑ **LO2**

Larry Hamill.

▲ **Figure 8–9**
Acne.

Courtesy of www.dermnet.com.

▲ **Figure 8–10**
Seborrheic dermatitis.

Reprinted with permission from the American Academy of Dermatology. All rights reserved.

▲ **Figure 8–11**
Rosacea.

Disorders of the Sudoriferous (Sweat) Glands

Anhidrosis (an-hih-DROH-sis) is a deficiency in perspiration, often a result of fever or certain skin diseases. Requires medical referral.

Bromhidrosis (broh-mih-DROH-sis) is foul-smelling perspiration, usually noticeable in the armpits or on the feet, that is caused by bacteria. Severe cases require medical referral.

Hyperhidrosis (hy-per-hy-DROH-sis) is excessive sweating, caused by heat or general body weakness. Requires medical referral.

Miliaria rubra (mil-ee-AIR-ee-ah ROOB-rah), also known as **prickly heat**, is an acute inflammatory disorder of the sweat glands, characterized by the eruption of small red vesicles and accompanied by burning, itching skin. It is caused by exposure to excessive heat and usually clears in a short time without treatment.

Inflammations and Common Infections of the Skin

Conjunctivitis (kuhn-juhngk-tuh-VAHY-tis), also known as **pinkeye**, is a common bacterial infection of the eyes. It is extremely contagious, and clients who have conjunctivitis or obviously irritated eyes should be politely rescheduled and referred to a physician immediately. Any product or implements touching infected eyes must be thrown away.

Dermatitis (dur-muh-TY-tis) is a term broadly used to describe any inflammatory condition of the skin.

Eczema (EG-zuh-muh) is an inflammatory, uncomfortable, and often chronic disease of the skin, characterized by moderate to severe inflammation, scaling, and sometimes severe itching. There are several different types of eczema. The most common type is atopic eczema, which is an inherited genetic disorder. All cases of eczema should be referred to a physician for treatment, which is often topical cortisone. Eczema is not contagious (**Figure 8–12**).

Courtesy of www.dermnet.com.

▲ **Figure 8–12**
Eczema.

Herpes simplex (HER-peez SIM-pleks) is a recurring viral infection that often presents as a fever blister or cold sore. It is characterized by the eruption of a single vesicle or group of vesicles on a red swollen base. The blisters usually appear on the lips, nostrils, or other part of the face, and the sores can last up to three weeks. Herpes simplex is contagious (**Figure 8–13**) and requires medical referral. Drugs are now available to control the symptoms, but the virus always remains in the body of infected persons.

Reprinted with permission from the American Academy of Dermatology. All rights reserved.

▲ **Figure 8–13**
Herpes simplex.

Impetigo (im-pet-EYE-go) is a contagious bacterial skin infection characterized by weeping lesions. Impetigo normally occurs on the face (especially the chin area) and is most frequently seen in children. Clients with any type of weeping open facial lesions should be politely rescheduled and referred to a physician immediately.

Psoriasis (suh-RY-uh-sis) is a skin disease characterized by red patches covered with silver-white scales and is usually found on the scalp, elbows, knees, chest, and lower back. Psoriasis is caused by the skin cells turning over faster than normal. It rarely occurs on the face. When the condition is irritated, bleeding points can occur. Psoriasis is not contagious (**Figure 8–14**), but it requires medical referral. It is treatable, but it is not curable.

Reprinted with permission from the American Academy of Dermatology. All rights reserved.

▲ **Figure 8–14**
Psoriasis.

Pigment Disorders of the Skin

Pigment can be affected by internal factors such as heredity or hormonal fluctuations, or by outside factors such as prolonged exposure

to the sun. Abnormal colorations, known as **dyschromias** (dis-chrome-ee-uhs), accompany skin disorders and many systemic disorders. A change in pigmentation can also be observed when certain drugs are being taken internally. The following terms relate to changes in the pigmentation of the skin:

Hyperpigmentation (hy-pur-pig-men-TAY-shun) means darker than normal pigmentation, appearing as dark splotches. **Hypopigmentation** (hy-poh-pig-men-TAY-shun) is the absence of pigment, resulting in light or white splotches.

Albinism (AL-bi-niz-em) is congenital hypopigmentation, or absence of melanin pigment in the body, including the skin, hair, and eyes. Hair is silky white. The skin is pinkish white and will not tan. The eyes are pink, and the skin is sensitive to light and ages early.

Chloasma (kloh-AZ-mah), also known as **liver spots**, is a condition characterized by hyperpigmentation on the skin in spots that are not elevated. This is just a commonly-used term; the spots have nothing to do with the liver. They are generally caused by cumulative sun exposure. They can be helped by exfoliation treatments or can be treated by a dermatologist.

Lentigines (len-TIJ-e-neez) (singular: lentigo, len-TY-goh) is the technical term for freckles, small yellow-colored to brown-colored spots on skin exposed to sunlight and air.

Leukoderma (loo-koh-DUR-muh) is a skin disorder characterized by light abnormal patches (hypopigmentation); it is caused by a burn or congenital disease that destroys the pigment-producing cells. Examples are vitiligo and albinism.

Nevus (NEE-vus), also known as **birthmark**, is a small or large malformation of the skin due to abnormal pigmentation or dilated capillaries.

Stain is an abnormal brown-colored or wine-colored skin discoloration with a circular or irregular shape (**Figure 8–15**). Its permanent color is due to the presence of darker pigment. Stains can be present at birth, or they can appear during aging, after certain diseases, or after the disappearance of moles, freckles, and liver spots. The cause is often unknown.

Tan is the change in pigmentation of skin caused by exposure to the sun or ultraviolet light.

Vitiligo (vi-til-EYE-goh) is a hereditary condition that causes hypopigmented spots and splotches on the skin that may be related to thyroid conditions (**Figure 8–16**). Skin with vitiligo must be protected from overexposure to the sun. ✓ LO3

▲ **Figure 8–15**
Port wine stain.

▲ **Figure 8–16**
Vitiligo.

CAUTION

Do not treat moles or remove hair from moles. Removing a hair from a mole could irritate or cause a structural change to it. Only a physician should remove a hair from a mole.

Hypertrophies of the Skin

A **hypertrophy** (hy-PUR-truh-fee) of the skin is an abnormal growth of the skin. Many hypertrophies are benign, which means they are harmless.

A **keratoma** (kair-uh-TOH-muh) is an acquired, superficial, thickened patch of epidermis. A callus is a keratoma that is caused by continued, repeated pressure or friction on any part of the skin, especially the hands and feet. If the thickening grows inward, it is called a corn.

A **mole** is a small brownish spot or blemish on the skin, ranging in color from pale tan to brown or bluish black. Some moles are small and flat, resembling freckles; others are raised and darker in color. Large dark hairs often occur in moles. Any change in a mole requires medical attention.

A **skin tag** is a small brown-colored or flesh-colored outgrowth of the skin (**Figure 8–17**). Skin tags occur most frequently on the neck of an older person. They can be easily removed by a dermatologist.

A **verruca** (vuh-ROO-kuh), also known as **wart**, is a hypertrophy of the papillae and epidermis. It is caused by a virus and is infectious. Verruca can spread from one location to another, particularly along a scratch in the skin. Requires medical referral.

▲ **Figure 8–17**
Skin tags.

▲ **Figure 8–18**
Basal cell carcinoma.

▲ **Figure 8–19**
Squamous cell carcinoma.

Skin Cancer

Skin cancer—primarily caused from overexposure to the sun—comes in three distinct forms that vary in severity. Each is named for the type of cells that it affects.

Basal cell carcinoma (BAY-zul SEL kar-sin-OH-muh) is the most common and the least severe type of skin cancer; it is often characterized by light or pearly nodules (**Figure 8–18**). **Squamous** (SKWAY-mus) **cell carcinoma** is more serious than basal cell carcinoma, and often is characterized by scaly red papules or nodules (**Figure 8–19**). The third and most serious form of skin cancer is **malignant melanoma** (muh-LIG-nent mel-uh-NOH-muh), which is often characterized by black or dark brown patches on the skin that may appear uneven in texture, jagged, or raised (**Figure 8–20**). Malignant melanoma is the least common—but also the most dangerous—type of skin cancer.

Clients should be advised to regularly see a dermatologist for checkups of the skin, especially if any changes in coloration, size, or shape of a mole are detected, if the skin bleeds unexpectedly, or a lesion or scrape does not heal quickly.

Home self-examinations can also be an effective way to check for signs of potential skin cancer between scheduled doctor visits. When performing a self-care exam, clients should be advised to check for any changes in existing moles and pay attention to any new visible growths on the skin.

If detected early, anyone with these three forms of skin cancer has a good chance for survival. Cosmetologists serve a unique role by being able to recognize the appearance of serious skin disorders and referring the client to a dermatologist for diagnosis and treatment.

▲ **Figure 8–20**
Malignant melanoma.

FYI

According to the American Cancer Society, professionals should use the ABCDE Cancer Checklist to spot signs of change in existing moles (Figure 8–21 a-f):

- **A** is for **ASYMMETRY:** the two sides of the lesion are not identical.
- **B** is for **BORDER:** the border is irregular on these lesions.
- **C** is for **COLOR:** melanomas are usually dark and have more than one color or colors that fade into one another.
- **D** is for **DIAMETER:** the lesion in a melanoma is usually at least the size of pencil eraser.
- **E** is for **EVOLVING:** melanoma as a lesion often changes appearance.

For more information, contact the American Cancer Society at http://www.cancer.org or (800) ACS-2345.

☑ LO4

▲ **Figure 8–21a**
Normal mole with normal symmetry. Both sides of the mole are the same.

▲ **Figure 8–21b**
A is for asymmetry. Abnormal mole has uneven symmetry. Two sides of the mole are not the same.

▲ **Figure 8–21c**
Normal mole with regular even borders.

▲ **Figure 8–21d**
B is for border. Abnormal mole has uneven or jagged borders.

▲ **Figure 8–21e**
Normal mole with even color.

▲ **Figure 8–21f**
C is for color. Abnormal mole, with more than one dark color.

Acne and Problem Skin

Common skin problems that affect clients' appearance, such as acne, can become a source of great concern. Most people have acne or another skin issue at some time in their lives. Acne is both a skin disorder and an esthetic problem, and it is a major concern to anyone who suffers from it. Frequently misunderstood to be a teenage skin disorder, it can affect people at almost any age. Women often do not have acne problems until they reach their 20s or 30s or beyond. Because it affects the appearance, it is of interest to cosmetologists and estheticians, who are in a position to help their clients with treatment for minor cases or to provide dermatological referral for more severe acne.

Acne is a disorder affected by two major factors: heredity and hormones. People with acne inherit the tendency to retain cells that gather on the walls of the follicle, eventually clumping and obstructing the follicle. **Retention hyperkeratosis** (hy-pur-kair-uh-TOH-sis) is the hereditary tendency for acne-prone skin to retain dead cells in the follicle, forming an obstruction that clogs follicles and exacerbates inflammatory acne lesions such as papules and pustules.

The oiliness of the skin is also hereditary. Overproduction of sebum by the sebaceous gland contributes to the development of acne by coating the dead cell buildup in the follicle with sebum, which hardens due to oxidation. This conglomeration of dead cells and solidified sebum obstruct the follicle.

Propionibacterium acnes are **anaerobic** (ann-air-ROH-bic), which means that these bacteria cannot survive in the presence of oxygen. When the follicles are obstructed, oxygen is blocked from the bottom of the follicles, allowing acne bacteria to multiply.

The main food source for acne bacteria is fatty acids, which are easily obtained from the abundance of sebum in the follicle. These bacteria flourish in this ideal environment, which is void of oxygen and with plenty of food (sebum) for the bacteria. The bacteria multiply, causing inflammation and swelling in the follicle, and eventually rupture the follicle wall. When the wall of the follicle ruptures, the immune system is alerted, causing blood to rush to the ruptured follicle, carrying white blood cells to fight the bacteria. Blood will surround and engulf the follicle, which is what causes the redness in pimples.

An acne papule is an inflammatory acne lesion resulting from this wall rupture and infusion of blood. A pustule forms from the papule when enough white blood cells accumulate to form pus, which is primarily composed of dead white blood cells.

did you know?

Skin cancer is preventable and early detection is possible, if you know what to look for. Be aware of the following as you service your clients:

- Any unusual lesions on the skin or on the scalp or change in an existing lesion or mole.
- Melanomas. These are sometimes found on the scalp and are often first detected by cosmetologists!
- A new lesion or discoloration on the skin or scalp.
- Client complaints about sores that do not heal or unexpected skin bleeding.
- Recurrent scaly areas that may be rough to the touch, especially in sun-exposed areas such as the face, arms, or hands.

If you become aware of any of these conditions, suggest that your client consult a physician.

Acne Treatment

Minor forms of acne can be treated without medical referral. The basics of acne treatment involve:

- The use of cleansers formulated for oily skin. These foamy, rinse-off products remove excess oil from the oily and acne-prone skin. Toners designed for oily skin help to further remove excess sebum.
- Follicle exfoliants are leave-on products that help to remove cell buildup from the follicles, allowing oxygen to penetrate the follicles, killing bacteria. Commonly used ingredients in these products are alpha hydroxy acid, salicylic acid, and benzoyl peroxide. Benzoyl peroxide can be especially effective since it helps to shed cellular debris and also kills the acne bacteria.
- Avoidance of fatty skin care and cosmetic products is important because products that contain large amounts of fatty materials and oils can cause follicles to clog from the outside. Make sure all makeup and skin care products used on acne-prone skin are **noncomedogenic** (non-com-EE-doh-JENN-ic), which means the product has been designed and proven not to clog the follicles.
- Do not use harsh products or over clean acne-prone skin as this can cause inflammation that can worsen the condition.
- Mild and moderate cases of acne are often treated by trained salon and spa professionals who have received specialized education in acne treatment. ✓ LO5

Aging Skin Issues

Aging of the skin is a concern of almost every client over thirty years of age. There are two types of factors that influence aging of the skin: intrinsic factors and extrinsic factors.

Intrinsic factors (in-TRIN-zic FAK-torz) are skin-aging factors over which we have little control:

- Genetic aging is how our parents' skin aged, their skin coloring and resistance to sun damage.
- Gravity is the constant pulling downward on our skin and bodies.
- Facial expressions are the repeated movements of the face that result in the formation of expression lines, such as crow's-feet lines that form around the eyes, nasolabial folds that form from the corners of the nose to the corners of the mouth, and scowl lines that form between the eyes.

Extrinsic factors (ex-TRIN-zic FAK-torz) are primarily environmental factors that contribute to aging and the appearance of aging. Many scientists and dermatologists believe that these extrinsic factors are responsible for up to 85 percent of skin aging. Extrinsic factors include:

- Exposure to the sun. Tanning and sun bathing are no-nos, but the cumulative sun that we get in little doses every day is the real

damage-causing sun for most people. Sun is by far the number one cause of the appearance of premature aging. The key to preventing this prominent skin-aging factor is to use a broad-spectrum sunscreen every single day, and the easiest way to do this is to find a daily-use moisturizer with built-in sunscreen. As a cosmetologist, you can help your clients find the best sunscreen and moisturizer to use every day.

- Smoking is bad for the body and the skin. It produces tremendous numbers of **free radicals**, unstable molecules that cause biochemical aging. These molecules, over time, can have a devastating effect on the body, especially wrinkling and sagging of the skin. Smoking causes oxygen deprivation of the skin and body, and it affects blood flow so the skin does not get adequate blood nutrients. Lack of blood flow also causes the accumulation of cellular waste, often called toxins.
- Overuse of alcoholic beverages also has an overall effect on the body and the skin. Alcohol abuse causes the body to repair itself poorly and interferes with proper nutrition distribution for the skin and body's tissues. Alcohol can also dehydrate the skin by drawing essential water out of the tissues, which causes the skin to appear dull and dry.

  Both smoking and overuse of alcoholic beverages contribute to the aging process on their own, but the combination of the two can be devastating to the tissues. The constant dilation and contraction that occur on the tiny capillaries and blood vessels, as well as the constant deprivation of oxygen and water to the tissues, quickly make the skin appear lifeless and dull. It is very difficult for the skin to adjust and repair itself. The damage done by these lifestyle habits is typically hard to reverse or diminish.
- The use of illegal drugs affects the skin as much as smoking does. Some drugs have been shown to interfere with the body's intake of oxygen, thus affecting healthy cell growth. Certain drugs can even aggravate serious skin conditions, such as acne. Others can cause dryness and allergic reactions on the skin's surface.
- Cumulative stress may significantly contribute to aging. Scientists are now learning that stress causes biochemical changes that can lead to the tissue damage that we call aging. Exercise, relaxation techniques, and a healthy state of mind can reduce stress levels, as can relaxing treatments like facials, aromatherapy, and massage.
- Poor nutrition deprives the skin of the proteins, fats, carbohydrates, vitamins, and minerals that are required to maintain, protect, and repair the skin, keeping it looking young and beautiful.
- Exposure to pollution produces free radicals and interferes with proper oxygen consumption. This affects the lungs and other internal organs, as well as the skin. The best defense against pollutants is the simplest one: follow a good daily skin care routine. Routine

washing and mild exfoliating (removing dead surface skin cells) help to remove the buildup of pollutants that have settled on the skin's surface throughout the day. The application of daily moisturizers, protective lotions, and even foundation products all help to protect the skin from airborne pollutants.

The appearance of aging skin can be greatly improved by practicing a good skin care program, especially at home. A professionally designed program for aging skin based on the client's needs, skin type, and condition severity involves a good hydrating sunscreen, an alpha or beta hydroxy acid exfoliating product, and products using state-of-the-art aging skin treatment ingredients such as peptides and topical antioxidants. ✓ **LO6**

The Sun and Its Effects

The sun and its ultraviolet (UV) light have the greatest impact of all extrinsic factors on how skin ages. Approximately 80 to 85 percent of the symptoms of aging skin are caused by the rays of the sun. As we age, the collagen and elastin fibers of the skin naturally weaken. This weakening happens at a much faster rate when the skin is frequently exposed to UV light without proper protection.

UVA rays, also known as *aging rays*, are deep-penetrating rays that can even go through a glass window. These rays weaken the collagen and elastin fibers, causing wrinkling and sagging of the tissues.

UVB rays, also known as *burning rays*, cause sunburns, tanning of the skin, and the majority of skin cancers. These are shorter rays that stop penetration at the base of the epidermis.

Here are some facts to pass on to your clients to educate them about sun safety and aging sun damage prevention:

- The number one way to prevent premature skin aging is to avoid deliberate sun exposure and to use a broad spectrum sunscreen, which is one that filters both UVA and UVB rays and has an SPF (Sun Protection Factor) of at least 15, on a daily basis.
- Avoid prolonged exposure to the sun during peak hours, when UV exposure is highest. This is usually between ten AM and three PM.
- Sunscreen should be applied at least thirty minutes before sun exposure to allow time for absorption. Many people make the mistake of applying sunscreen after they have been exposed to the heat and sun for thirty minutes or more. The already inflamed skin is more

likely to react to the sunscreen chemicals when the sunscreen is applied after sun exposure.

- Apply sunscreen liberally after swimming and after activities that result in heavy perspiration. If the skin is exposed to hours of sun, such as during a boat trip or day at the beach, sunscreen should be applied periodically throughout the day as a precaution.
- Avoid exposing children younger than six months of age to the sun.
- People who are prone to burning frequently and easily should wear a hat and protective clothing when participating in outdoor activities, in addition to using sunscreen. Redheads and blue-eyed blonds are particularly susceptible to sun damage. ✓ LO7

Contact Dermatitis

Contact dermatitis is the most common work-related skin disorder for all cosmetology professionals. **Contact dermatitis** is an inflammation of the skin caused by having contact with certain chemicals or substances. Many of these substances are commonly used in cosmetology. There are two types of contact dermatitis: Allergic Contact Dermatitis and Irritant Contact Dermatitis.

Allergic Contact Dermatitis

Allergic contact dermatitis, abbreviated ACD, occurs when the person (cosmetologist or client) develops an allergy to an ingredient or a chemical, usually caused by repeated skin contact with the chemical. **Sensitization** is an allergic reaction created by repeated exposure to a chemical or a substance. Monomer liquids, haircolor, and chemical texture solutions are all capable of causing allergic reactions with repeated exposures.

Once an allergy has been established, all services must be discontinued until the allergic symptoms clear. The person affected by the allergy (cosmetologist or client) must stop using that particular product. In severe or chronic cases, affected people should see a dermatologist for allergy testing.

Common places for allergic contact dermatitis are listed below and include:

- On the fingers, palms, or on the back of the hand.
- On the face, especially the cheeks.
- On the scalp, hairline, forehead, or neckline.

If you examine the area where the problem occurs, you can usually determine the cause. For example, haircolorists often strand test color with their bare fingers and hands, so it is no surprise when they find contact dermatitis on their fingers and hands.

Irritant Contact Dermatitis

Irritant contact dermatitis, abbreviated ICD, occurs when irritating substances temporarily damage the epidermis. Unlike allergic contact dermatitis, irritant contact dermatitis is not usually chronic if precautions are taken.

Corrosive substances or exfoliating agents are examples of products with irritant potential. Contact with irritant chemicals can cause damage to the epidermis because the irritant can enter the skin surface and cause possible inflammation, redness, swelling, itching, and burning. Repeated exposure can worsen the condition.

The way to prevent both types of occupational contact dermatitis is to use gloves or utensils when working with irritating chemicals. Cosmetologists should use gloves or utensils when applying chemicals such as haircolor, straighteners, or permanent wave solutions. Nail technicians should use gloves or utensils when applying nail products such as monomer liquids and polymer powders. Estheticians should use gloves or utensils when applying exfoliants such as peeling products and drying agents. All of these chemicals can irritate the skin of the hands and arms if precautions are not taken to avoid contact.

Frequent hand washing can result in dry hands, with cracks in the skin that can cause more irritation and that can allow penetration of irritant chemicals. Hand washing is important to prevent the spread of disease, but it should be followed by the frequent use of protective hand creams to keep the hands in good condition. ✓ LO8

Protect Yourself

Taking the time to keep your implements, tools, equipment, and surfaces clean and disinfected is an important step in protecting yourself and avoiding a skin problem. Practice these suggestions with great diligence:

- Take extreme care to keep brush handles, containers, and table tops clean and free from product, dust, and residue. Repeatedly handling these items will cause overexposure if the items are not kept clean.
- Wear protective gloves whenever using products known to cause irritant or allergic contact dermatitis.
- Keep your hands clean and moisturized. Keeping the skin of the hands in excellent condition will help prevent irritant reactions.

Review Questions

1. What is a skin lesion?
2. Name and describe at least five disorders of the sebaceous glands.
3. Name and describe at least five changes in skin pigmentation.
4. What are the three forms of skin cancer?
5. What are the two major causes of acne and how should they be effectively treated?
6. List the factors that contribute to the aging of the skin.
7. Explain the skin effects of overexposure to the sun.
8. What is contact dermatitis and how can it be prevented?

Chapter Glossary

albinism	Congenital hypopigmentation, or absence of melanin pigment of the body, including the skin, hair, and eyes.
allergic contact dermatitis	Abbreviated ACD; an allergy to an ingredient or a chemical, usually caused by repeated skin contact withthe chemical.
anaerobic	Cannot survive in the presence of oxygen.
anhidrosis	Deficiency in perspiration, often a result of fever or certain skin diseases.
basal cell carcinoma	Most common and least severe type of skin cancer; often characterized by light or pearly nodules.
bromhidrosis	Foul-smelling perspiration, usually noticeable in the armpits or on the feet, that is caused by bacteria.
bulla (plural: bullae)	Large blister containing a watery fluid; similar to a vesicle but larger.
chloasma	Also known as *liver spots*; condition characterized by hyperpigmentation on the skin in spots that are not elevated.
closed comedo	Also known as *whitehead*; hair follicle is closed and not exposed to the environment; sebum remains a white or cream color and comedone appears as small bump just under the skin surface.
conjunctivitis	Also known as *pinkeye*; common bacterial infection of the eyes; extremely contagious.
contact dermatitis	An inflammation of the skin caused by having contact with certain chemicals or substances; many of these substances are used in cosmetology.

Chapter Glossary

crust	Dead cells that form over a wound or blemish while it is healing; an accumulation of sebum and pus, sometimes mixed with epidermal material.
cyst	Closed, abnormally developed sac that contains fluid, pus, semifluid, or morbid matter above or below the skin.
dermatitis	Inflammatory condition of the skin.
dyschromias	Abnormal colorations of the skin that accompany many skin disorders and systemic disorders.
eczema	An inflammatory, uncomfortable, and often chronic disease of the skin, characterized by moderate to severe inflammation, scaling, and sometimes severe itching.
excoriation	Skin sore or abrasion produced by scratching or scraping.
extrinsic factors	Primarily environmental factors that contribute to aging and the appearance of aging.
fissure	A crack in the skin that penetrates the dermis. Examples are severely cracked and/or chapped hands or lips.
free radicals	Unstable molecules that cause biochemical aging, especially wrinkling and sagging of the skin.
herpes simplex	Recurring viral infection that often presents as a fever blister or cold sore.
hyperhidrosis	Excessive sweating, caused by heat or general body weakness.
hyperpigmentation	Darker than normal pigmentation, appearing as dark splotches.
hypertrophy	Abnormal growth of the skin.
hypopigmentation	Absence of pigment, resulting in light or white splotches.
impetigo	Contagious bacterial skin infection characterized by weeping lesions.
intrinsic factors	Skin-aging factors over which we have little control.
irritant contact dermatitis	Abbreviated ICD; occurs when irritating substances temporarily damage the epidermis.
keloid	Thick scar resulting from excessive growth of fibrous tissue.
keratoma	Acquired, superficial, thickened patch of epidermis. A callus is a keratoma caused by continued, repeated pressure or friction on any part of the skin, especially the hands and feet.
lentigines (singular: lentigo)	Technical term for freckles; small yellow-colored to brown-colored spots on skin exposed to sunlight and air.
lesion	Mark on the skin; may indicate an injury or damage that changes the structure of tissues or organs.

Chapter Glossary

leukoderma	Skin disorder characterized by light abnormal patches (hypopigmentation); caused by a burn or congenital disease that destroys the pigment-producing cells.
macule (plural: maculae)	Flat spot or discoloration on the skin, such as a freckle or a red spot left after a pimple has healed.
malignant melanoma	Most serious form of skin cancer; often characterized by black or dark brown patches on the skin that may appear uneven in texture, jagged, or raised.
milia	Benign, keratin-filled cysts that can appear just under the epidermis and have no visible opening.
miliaria rubra	Also known as *prickly heat*; an acute inflammatory disorder of the sweat glands, characterized by the eruption of small red vesicles and accompanied by burning, itching skin.
mole	Small, brownish spot or blemish on the skin, ranging in color from pale tan to brown or bluish black.
nevus	Also known as *birthmark*; small or large malformation of the skin due to abnormal pigmentation or dilated capillaries.
nodule	A solid bump larger than .4 inches (1 centimeter) that can be easily felt.
noncomedogenic	Product that has been designed and proven not to clog the follicles.
primary lesions	Lesions that are a different color than the color of the skin, and/or lesions that are raised above the surface of the skin.
psoriasis	Skin disease characterized by red patches covered with silver-white scales; usually found on the scalp, elbows, knees, chest, and lower back.
retention hyperkeratosis	The hereditary tendency for acne-prone skin to retain dead cells in the follicle, forming an obstruction that clogs follicles and exacerbates inflammatory acne lesions such as papules and pustules.
rosacea	Chronic condition that appears primarily on the cheeks and nose, and is characterized by flushing (redness), telangiectasis (distended or dialted surface blood vessels), and, in some cases, the formation of papules and pustules.
scale	Any thin dry or oily plate of epidermal flakes. An example is abnormal or excessive dandruff.
scar	Also known as *cicatrix*; a lightly raised mark on the skin formed after an injury or lesion of the skin has healed.

Chapter Glossary

sebaceous cyst	A large protruding pocket-like lesion filled with sebum. Sebaceous cysts are frequently seen on the scalp and the back. They should be removed surgically by a dermatologist.
seborrheic dermatitis	Skin condition caused by an inflammation of the sebaceous glands. It is often characterized by redness, dry or oily scaling, crusting, and/or itchiness.
secondary skin lesions	Characterized by piles of material on the skin surface, such as a crust or scab, or depressions in the skin surface, such as an ulcer.
sensitization	Allergic reaction created by repeated exposure to a chemical or a substance.
skin tag	A small brown-colored or flesh-colored outgrowth of the skin.
squamous cell carcinoma	Type of skin cancer more serious than basal cell carcinoma; often characterized by scaly red papules or nodules.
stain	Abnormal brown-colored or wine-colored skin discoloration with a circular and/or irregular shape.
tan	Change in pigmentation of skin caused by exposure to the sun or ultraviolet light.
telangiectasis	Distended or dilated surface blood vessels.
tubercle	Abnormal, rounded, solid lump above, within, or under the skin; larger than a papule.
tumor	An abnormal mass varying in size, shape, and color.
ulcer	Open lesion on the skin or mucous membrane of the body, accompanied by pus and loss of skin depth and possibly weeping fluids or pus.
verruca	Also known as *wart*; hypertrophy of the papillae and epidermis.
vesicle	Small blister or sac containing clear fluid, lying within or just beneath the epidermis.
vitiligo	Hereditary condition that causes hypopigmented spots and splotches on the skin; may be related to thyroid conditions.
wheal	Itchy, swollen lesion that lasts only a few hours; caused by a blow or scratch, the bite of an insect, urticaria (skin allergy), or the sting of a nettle. Examples include hives and mosquito bites.